
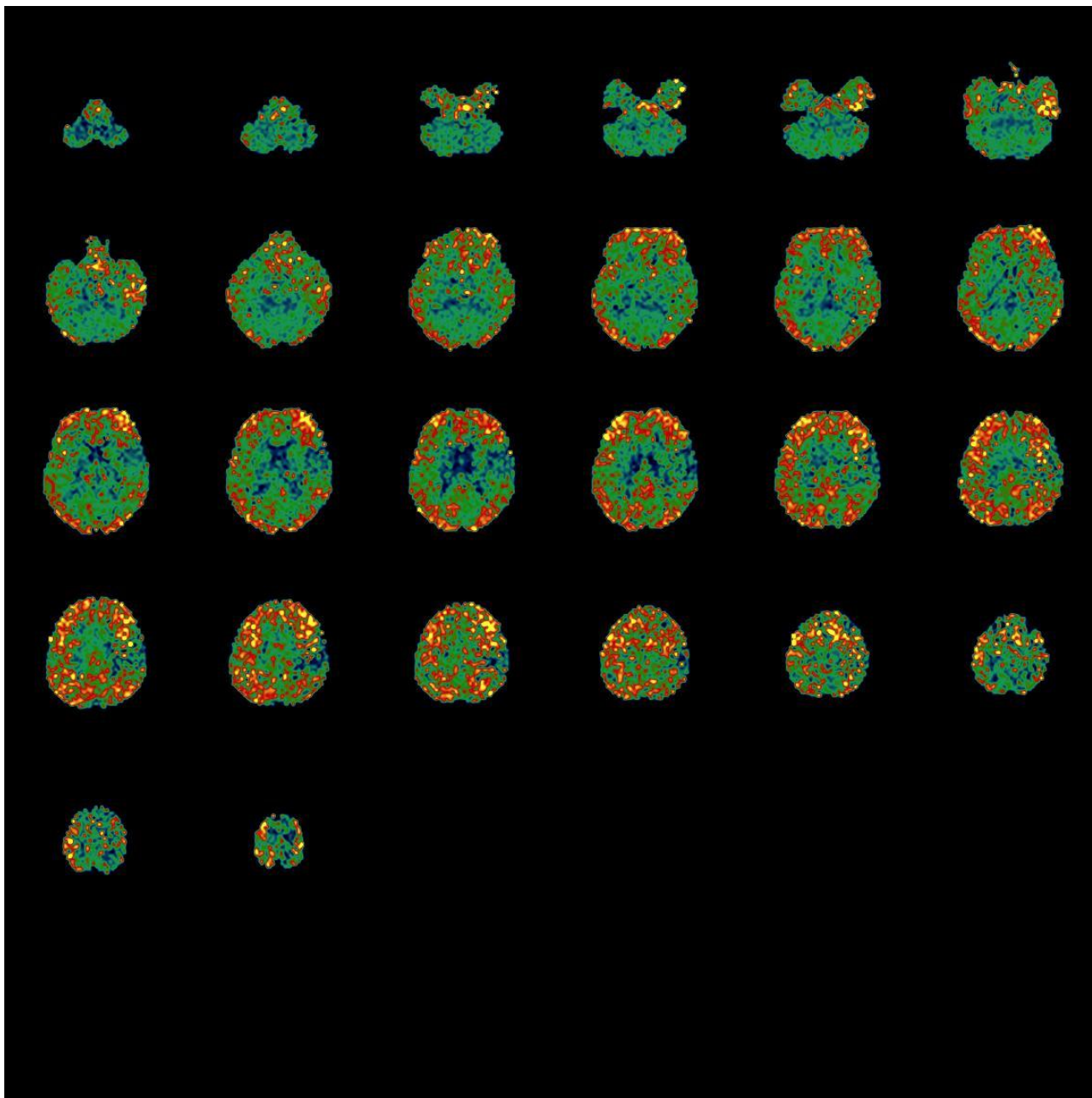




ACBV Report

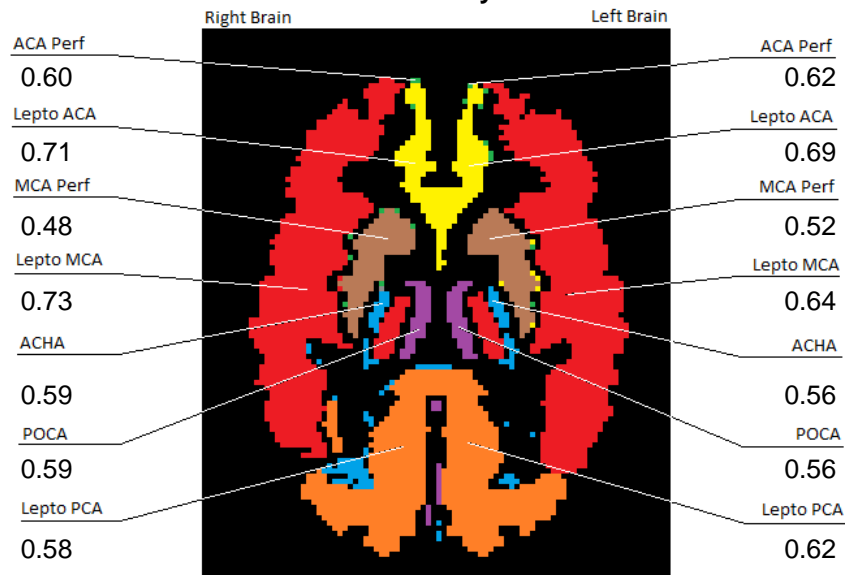
Name:		Gender:	F	Age:	056Y
Patient ID:		Case ID:	0010000984		
Study Date:	2019-06-14 17:08:44	Analysis Date:	2019-06-17 09:34:17		
Institution:		Physician:			



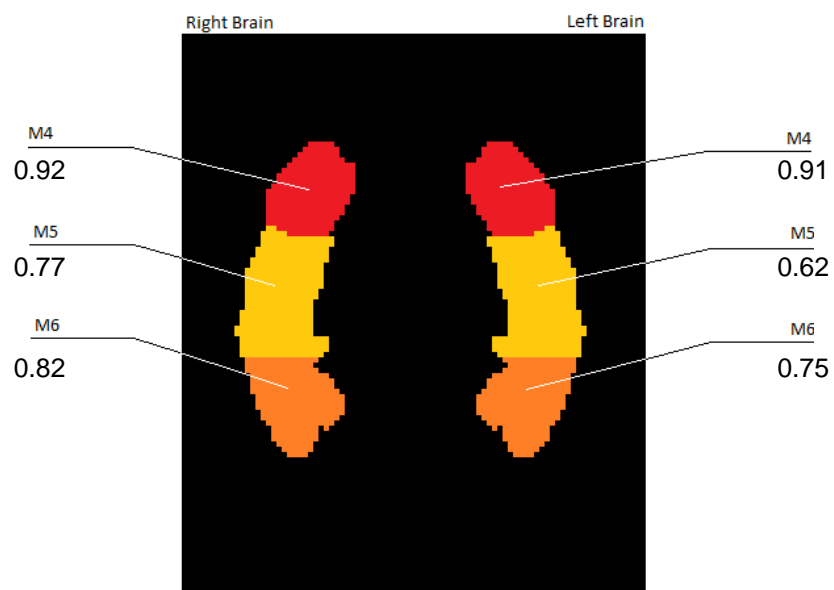
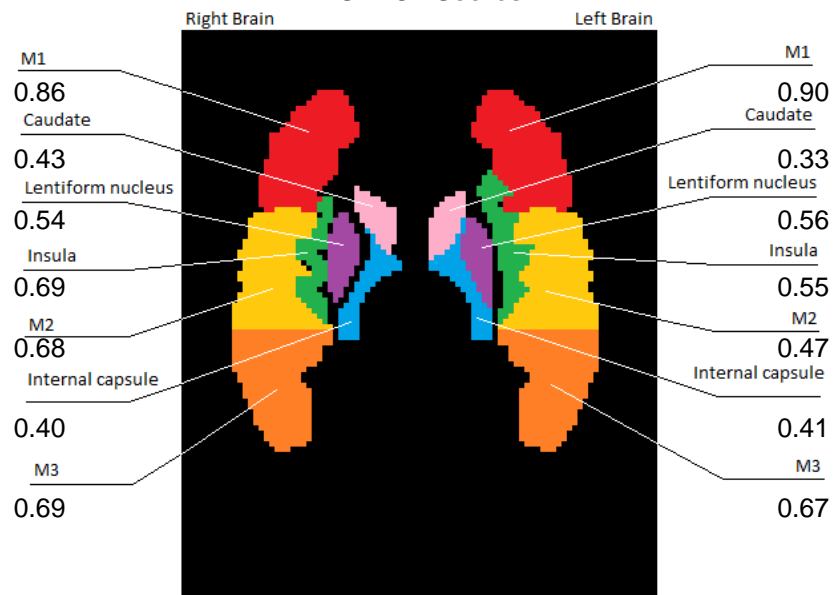
Global Mean: 0.72

Global Standard Deviation: 0.24

Vascular Territory Scores



ASPECT Scores



Global Mean:0.72
Right Global Mean:0.76
Left Global Mean:0.68

Standard Deviation:0.24
Right Standard Deviation:0.21
Left Standard Deviation:0.25

Vascular Territory

Name	Right	Left	Asymmetry
ACAPerf	0.60	0.62	0.01
ACHA	0.59	0.56	0.03
LeptoACA	0.71	0.69	0.02
LeptoMCA	0.73	0.64	0.06
LeptoPCA	0.58	0.62	0.03
MCAPerf	0.48	0.52	0.04
POCA	0.59	0.56	0.03

ASPECT

Name	Right	Left	Asymmetry
Insula	0.69	0.55	0.12
Caudate	0.43	0.33	0.13
LentiformNucleus	0.54	0.56	0.02
InternalCapsule	0.40	0.41	0.01
M1	0.86	0.90	0.02
M2	0.68	0.47	0.19
M3	0.69	0.67	0.02
M4	0.92	0.91	0.01
M5	0.77	0.62	0.11
M6	0.82	0.75	0.04